




Bilaga till RAS- Rasspecifika Avels Strategier för borzoi
Enligt beslut årsmöte 2010, fastställd årsmöte 2011, reviderad 2011-07-12
Sanktionerad av SKKs Domarkommitté, möte 2011-06-09, § 92
Översatt till engelska 2015-05-15

Canines and bite

IN THE BORZOI BREED





Bilaga till RAS- Rasspecifika Avels Strategier för borzoi
Enligt beslut årsmöte 2010, fastställd årsmöte 2011, reviderad 2011-07-12
Sanktionerad av SKKs Domarkommitté, möte 2011-06-09, § 92
Översatt till engelska 2015-05-15

PRELUDE

At the revision and finalization of the RAS (Rasspecifika Avels Strategier -breed specific breeding strategies) at Borzoi-Ringen's annual meeting it was decided that this appendix was to be created as an aid to help judges and breeders in their assessments of the placement of the lower canine teeth in the individual borzoi.

It has been noted that the judges assess the placement of the lower canines with great variety, which is a cause of confusion for the novice breeder and exhibitor as well as a source of annoyance for the experienced breeders and exhibitors.

It is of great importance that no single fault gains too much importance so that it will have a negative outcome for the breed. A deviation must not be interpreted so that dogs with a correct bite for the breed are incorrectly faulted.

BSI

In 2008 the Swedish Kennel Club introduced BSI- Breed Specific Instructions, regarding exaggerations in pedigree dogs. Breeds with exaggerations were to be listed with annotation accordingly so that the judges would pay extra attention and report their observations.

The borzoi received an annotation by the BSI-committee regarding canine teeth placement which, as of the revision in 2014, states as follows:

Mouth: Incorrectly placed canine teeth.

The breed standard gives clear information: Eliminating fault: "Faulty position of one or both canines of the lower jaw which, when the mouth is shut, can damage the upper gums or the palate."



BITES AND JAWS

In the FCI standard (FCI-St. N° 193 / 22.11.2006) you will find the muzzle and jaw described as:

Muzzle: The length of the muzzle from the stop to the tip of the nose is equal or slightly superior to that of the skull, from the occiput to the stop.

Jaws/Teeth: Strong underjaw. Teeth white, strong; scissor bite or pincer bite.

Listed in the FCI standard as disqualifying faults:

- Overshot or undershot mouth.
- Wry mouth.
- Faulty position of one or both canines of the lower jaw which, when the mouth is shut, can damage the upper gums or the palate.

It is a fact that severely incorrect bites have an apparent link to the development of the jaws. This is evident in severe over- [image 1] and under shot [image 2] bites and also in base-narrow mandibular canine teeth.

In the following we are particularly elaborating the deviation of the position of lower canines

Image 1



Image 1

Severe overshoot bite due to an underdeveloped lower jaw. This type of anomaly may cause the canines going up into the palate

Image 2




Image 2

When the upper jaw is shortened this may cause a severe under shot bite and creates an exaggerated curvature of the top line of the muzzle creating an over typed face profile aka "Roman head". In Russia this type of head is considered very beautiful.



Bilaga till RAS- Rasspecifika Avels Strategier för borzoi
Enligt beslut årsmöte 2010, fastställd årsmöte 2011, reviderad 2011-07-12
Sanktionerad av SKKs Domarkommitté, möte 2011-06-09, § 92
Översatt till engelska 2015-05-15

Image 3 & 4



Image 3 & 4

The lower jaw is too narrow and may cause the canines to place the inside of the teeth in the upper jaw and thereby touch the palate.

Minor incorrect bites are the "reversed scissors bite"; a slight undershot bite, or the very slight overshot bite, which are not obvious until you open the dogs mouth to check the bite.

Image 5

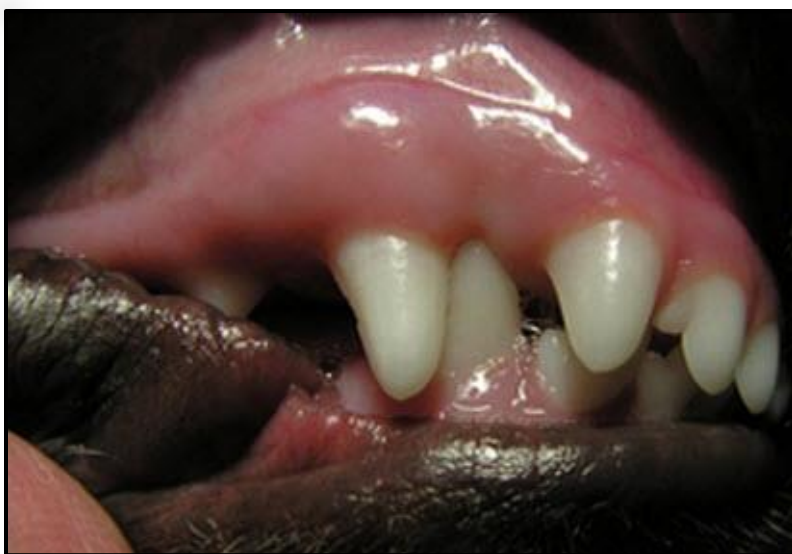

Image 5

This picture displays the lower canines going up into the palate. This may be seen in dogs with any type of bite, scissors, level, reversed scissors, undershot overshot bites.

It is not always the case that the canines will cause damage to the palate, even so suffering from base narrow canines. Even so, it is undesirable and a disqualifying fault.



THE PALATE

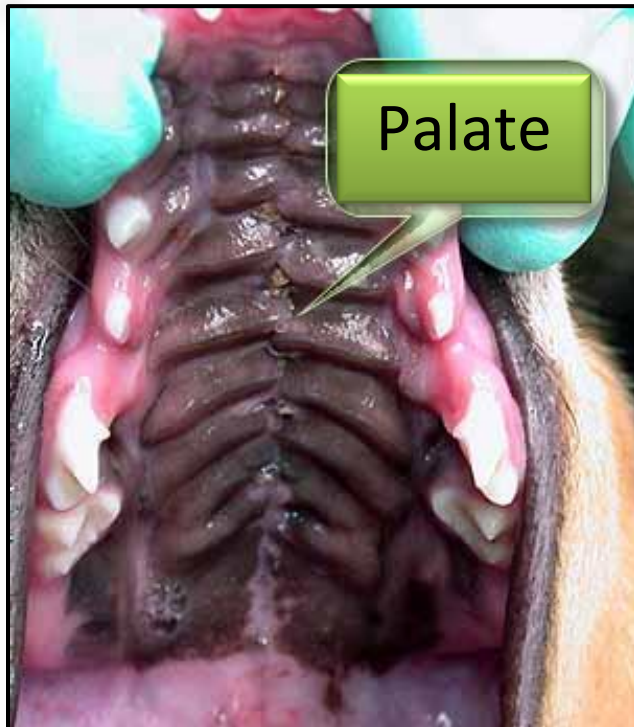

Image 6

The palate is the roof of the oral cavity between the teeth of the upper jaw as displayed in image 6

Evaluation of a bite regarding the lower canines touching the palate should not be difficult for inexperienced owners, breeders or judges.

Lower canines touching the palate [Image 6] is a disqualifying fault as stated in the breed standard.

“Base narrow canines/Base-Narrow Mandibular Canine Teeth”, which is the clinical term, may occur in any breed. Treatment options for base narrow canines include orthodontic repositioning, surgical repositioning, crown height reduction, and extractions. However, such undertaking makes the dog ineligible for shows.

GENETIC BACKGROUND

Breeders and judges should be aware of the fact that there are more than 15 different genes influencing the development of the lower jaw (mammalian mandible). There are equally many genes that determine the development of the upper jaw (maxillary complex). The influences of these genes are comparatively autonomous to each other and thereof the type of conformation of the two jaws may origin from the two parents and thus explaining why they do not always fit perfectly together. The borzoi is displaying several different head types, equally correct from the conformation perspective and proving the great genetic variety which can explain deviations in the jaws and teeth.

CORRECT BITES

A correct bite for the borzoi is either a scissors or a level bite with the lower canines teeth placed on the outside of the upper row of teeth and in front of the upper jaw canine.

It is neither a requirement nor a functional purpose to demand the lower canines to be placed completely outside and free from touching the gums. The lower canines of the borzois are usually placed so they align/touch the outside of the gums without causing lesion and this is due to the typical shape of the borzoi head. Freely placed canines serve no function or purpose in itself.



Bilaga till RAS- Rasspecifika Avels Strategier för borzoi
Enligt beslut årsmöte 2010, fastställd årsmöte 2011, reviderad 2011-07-12
Sanktionerad av SKKs Domarkommitté, möte 2011-06-09, § 92
Översatt till engelska 2015-05-15

Image 7

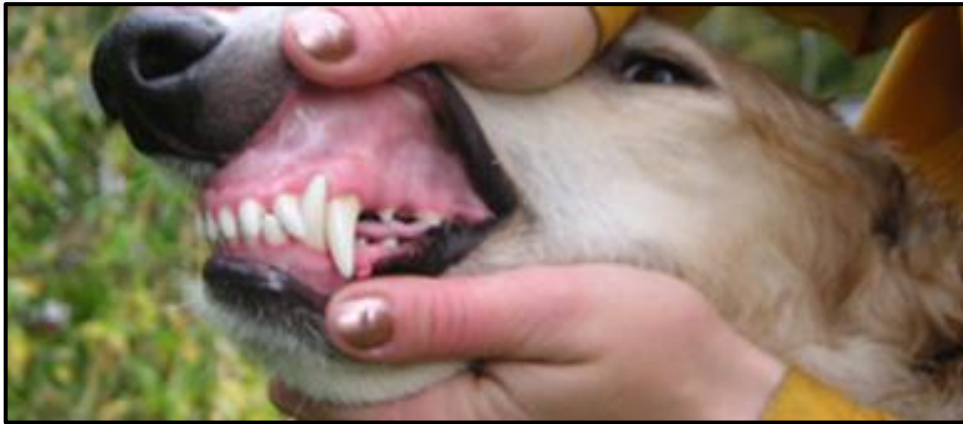

Image 7 Excellent bite with long canine teeth.

As previously mentioned the breed standard states the following as a disqualifying fault "Faulty position of one or both canines of the lower jaw which, when the mouth is shut, can damage the upper gums or the palate". The risk of damaging the palate is obvious with faulty position of lower canines. The interference with the palate/gums must be especially focused.

This is to be considered regarding the correct fact that the upper gum may have an imprint like a dent fitting the top shape of the lower canine as seen in figure 8. This is a correct bite as long as there are no signs of damage or granuloma.

Image 8

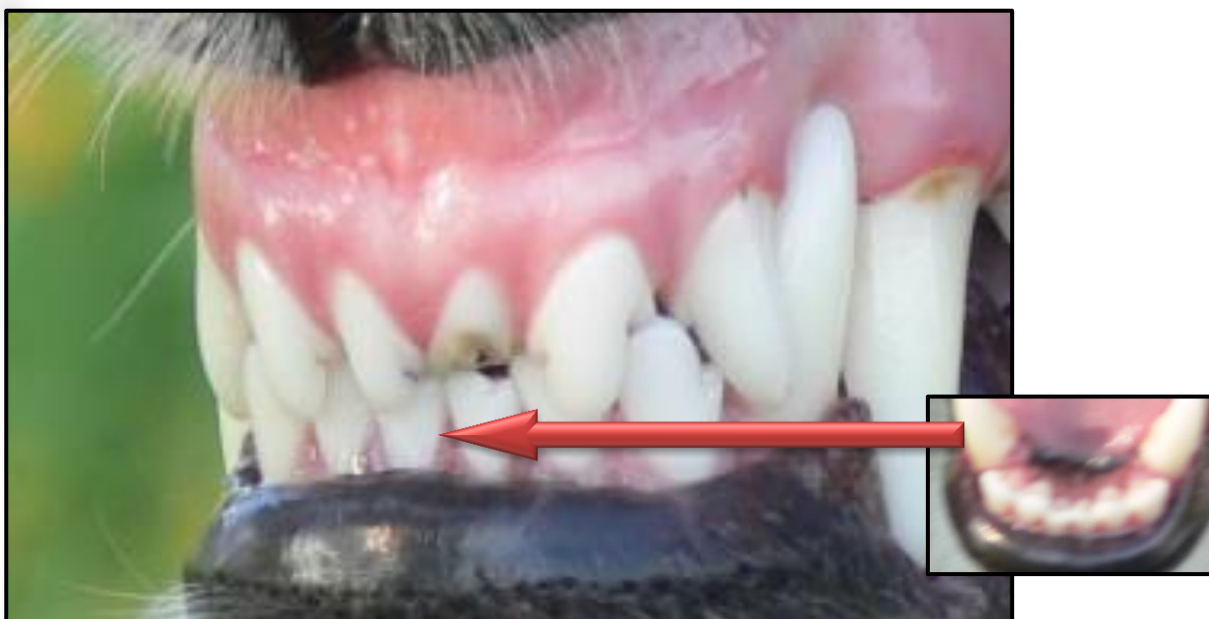

Image 8 shows a good broad lower jaw, with the incisors in a straight line. More commonly seen is that the incisors are placed aligned forming a soft curve. The dog pictured have somewhat short canines.



Image 9

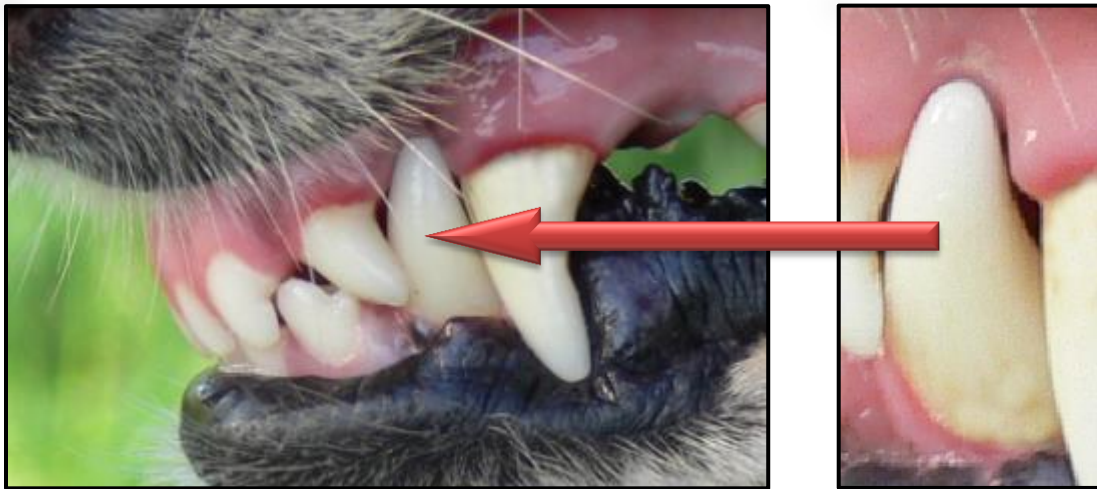


Image 9

A correct bite but with short canines. As seen in the enlargement of the lower canine there are no lesions or any other damage to the gums.

Image 10

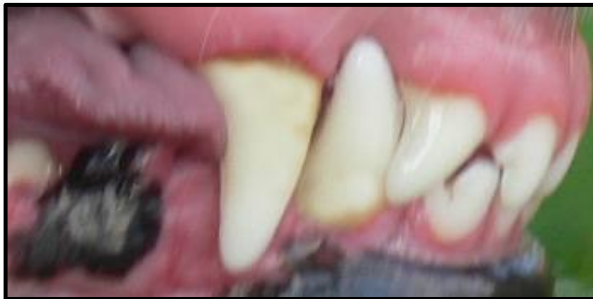

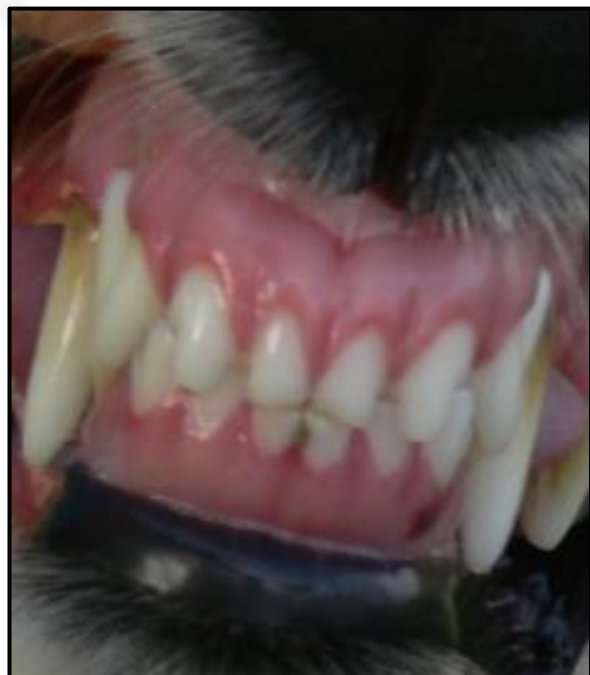Image 10 Displays a correct bite

Image 11

Image 11 The position of the borzoi canines are more upright set than seen in many other breeds.

As a guideline: You should be able to see the tip of the lower canine when the mouth is closed.

The impression in the upper gum from the canine tooth should not be as deep, so that the tip of the canine is no longer visible.





Bilaga till RAS- Rasspecifika Avels Strategier för borzoi
Enligt beslut årsmöte 2010, fastställd årsmöte 2011, reviderad 2011-07-12
Sanktionerad av SKKs Domarkommitté, möte 2011-06-09, § 92
Översatt till engelska 2015-05-15

Image 12

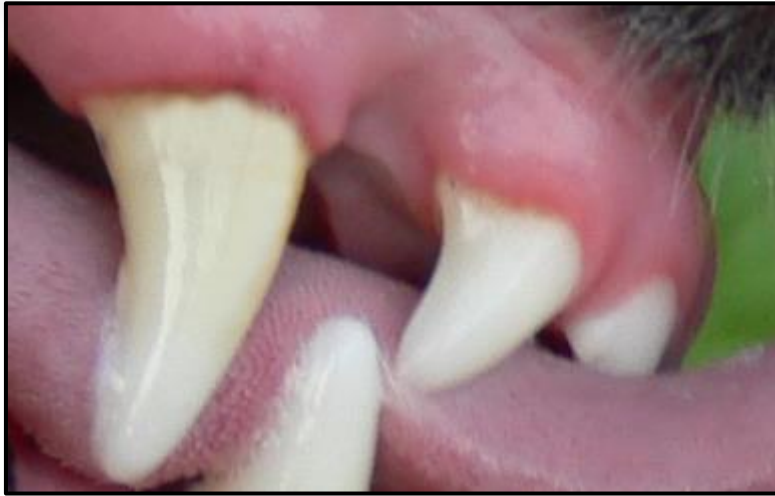

Image 12

Same bite as in images 10 and 11. Illustrates healthy and undamaged gums.

The Swedish National Specialty in 2010 was judged by breed specialist Mila Pantaleeva, Vega Shelk borzois, from Russia- the home country of borzoi. She wrote the following statement for the breed club after her assignment;

“The head of the Borzoi is the breed’s « emblem». The Borzoi should have an elegant head with aristocratic lines and a correct substance. But we shouldn’t forget that the Borzoi’s head is a working breed dog’s head. It’s amazingly beautiful head is the dog’s working tool. Many of Swedish Borzoi boasts beautiful heads of a pedigree dog with a correct substance.

Though I think that some of your Borzoi should have a narrower skull the skull size still isn’t beyond the breed standards. Some males have a heavy and hollow skull though it is allowed for males. Also I saw fine heads of old Russian classical type and a very rare type of a head a Roman head. And I observed correct proportion of the upper jaw and under jaw, and moreover, all of the examined borzois boasted a standard bite. I either didn’t find serious deficiency of teeth. All your borzois feature excellent pigmentation. Only two dogs had subdued pigmentation.”

THE BITE AND AGE

As most of us are aware of, with age a bite may change. Most long term breeders have experienced having puppies with their baby canines touching the palate or pinching up in the gums in an undesired manner- but with age and the development adult teeth a perfectly correct bite is obtained.

It is also seen in older puppies (4-6 mos.) after changing teeth that the bite may appear to be incorrect, due to the lower canine being placed on the inside of the upper canines. This is most often due to the canines have not yet fully emerged, and will temporary be an incorrect bite in the puppy, see image 13. When the canines have emerged to their full length, the dog will likely have a correct bite.



Image 13

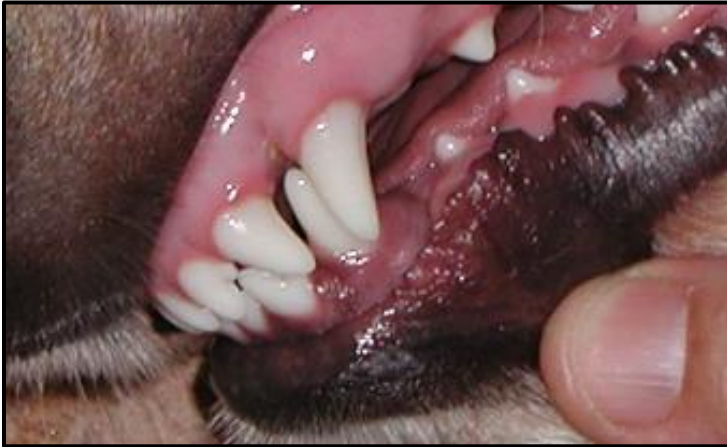

Image 13-

A puppy with the lower canines at this stage placed on the insides of the upper canines. This pup developed a correct bite when the canines were fully emerged.

As in aged humans as well as in old dogs, the mouth will change and usually not for the better. It has been noted that there is a tendency to shorter canines in the breed and these may embed themselves deeper in the gums as the dog grows older. Usually this will cause the dog no trouble or pain, and the bite will remain functional, but it may not be as "pretty". A dog with long canines will keep a perfect bite through out their lives (granted they had one to start with) as the upper jaw will work as "braces" helping them to stay in place.

A dog with a bite that have tightly or incorrect placed canines will often be evaluated as having a narrow under jaw- which not always may be the case, when the canines are short.

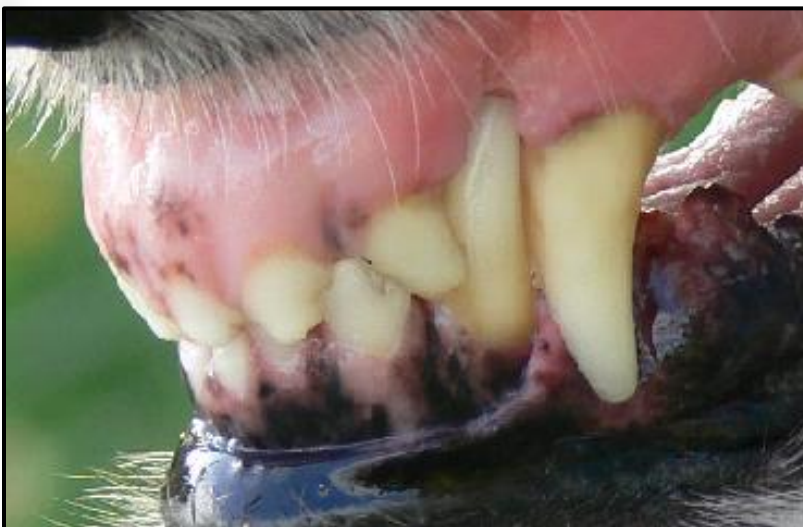

Image 14

Image 14-

Pictured a bitch over 10 years of age who had a correct bite at younger years but her canines have now embedded themselves into the upper gum at this age. Considering her old age, this would make an excusable bite and must not necessarily be penalized in the ring. Her bite is still functional and does not cause her any pain or discomfort.

If this dog pictured in image 14 has had longer canines, they would have remained in correct position throughout its life. No matter what age the dogs are, the teeth are not to be allowed to cause the dog any pain or lesions. If the dog is suffering from any dental problem, as base narrow canines, or any other dental problem- it should be taken to the vet and get proper dental care. A dog which has undergone surgical correction it is no longer admissible to attend the SKC dog shows.

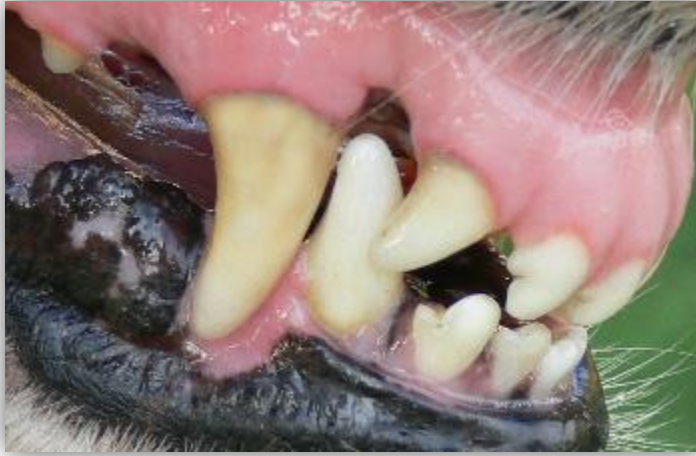

Image 15-

Same bitch as in image 14. It is here obvious that the embedded canines do not inflict any harm to her gums. There are no indications of lesions or any other irritations- her gums have a healthy pink color.

Image 15

WHAT IS MALOCCLUSION

Malocclusion refers to abnormal positioning of the animal's dentition. When malocclusion causes discomfort or interferes with normal function, it should be addressed. A common painful malocclusion seen in veterinary patients is Base-Narrow Mandibular Canine Teeth (BNMCT). The most common orthodontic abnormality seen in dogs (all breeds) is BNMCT. The normal position for mandibular canine teeth is the diastema between the maxillary third incisors and canine teeth, resting labial (lateral) to the maxillary gingival tissues. In BNMCT, the lower canine teeth occlude closer to the midline, commonly traumatizing the palate and causing painful ulcerated soft tissue lesions.

To demonstrate the patient's discomfort with BNMCT, simply press the maxilla and mandible together firmly. The reaction of the patient leaves little doubt about the painful nature of this condition. This test should be performed at a veterinarian's office and not in a show ring.

ILLUSTRATIONS OF CORRECT BITES

Following pictures illustrates correct bites for borzoi

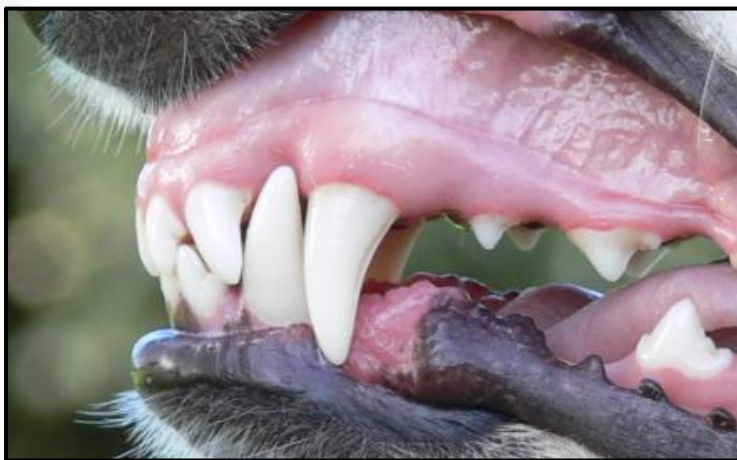

Image 16

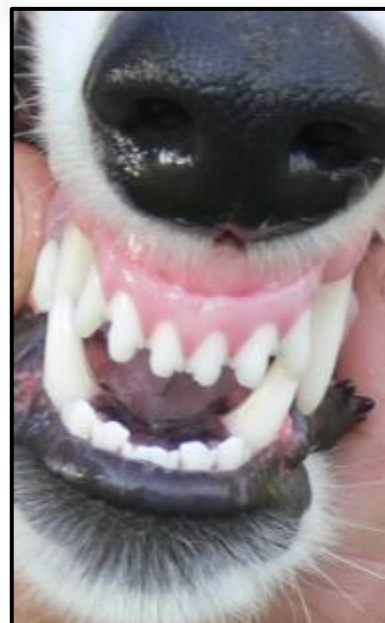

Image 17



Bilaga till RAS- Rasspecifika Avels Strategier för borzoi
Enligt beslut årsmöte 2010, fastställd årsmöte 2011, reviderad 2011-07-12
Sanktionerad av SKKs Domarkommitté, möte 2011-06-09, § 92
Översatt till engelska 2015-05-15

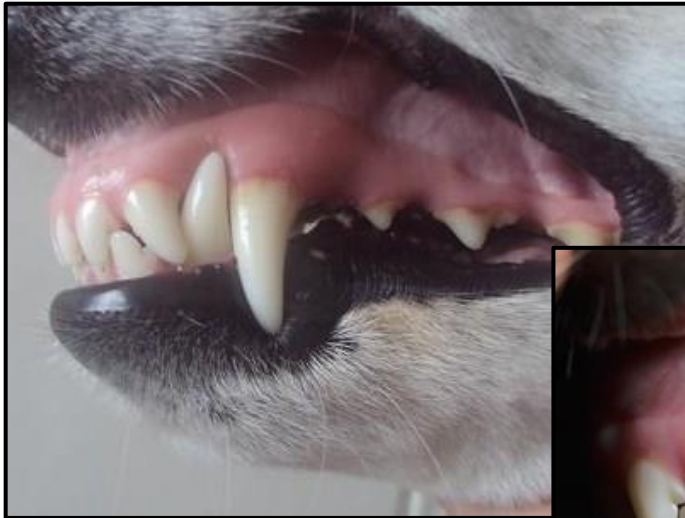

Image 18

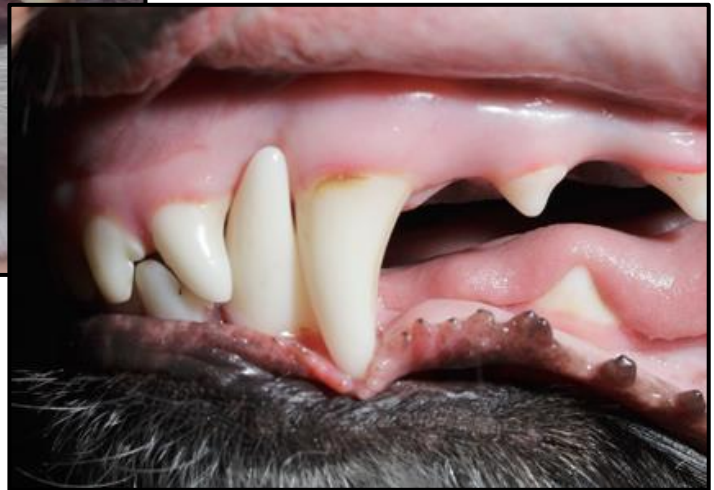

Image 20

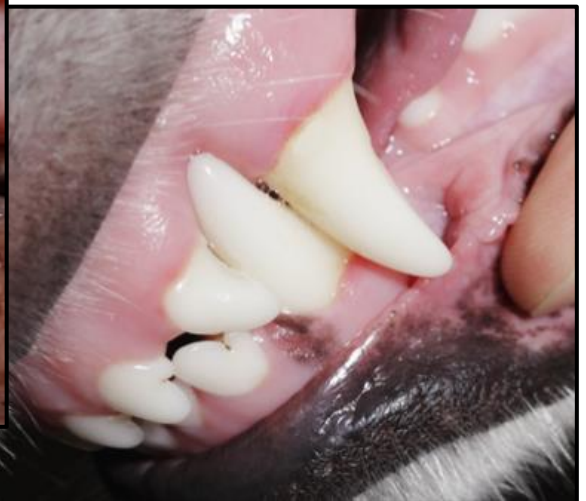
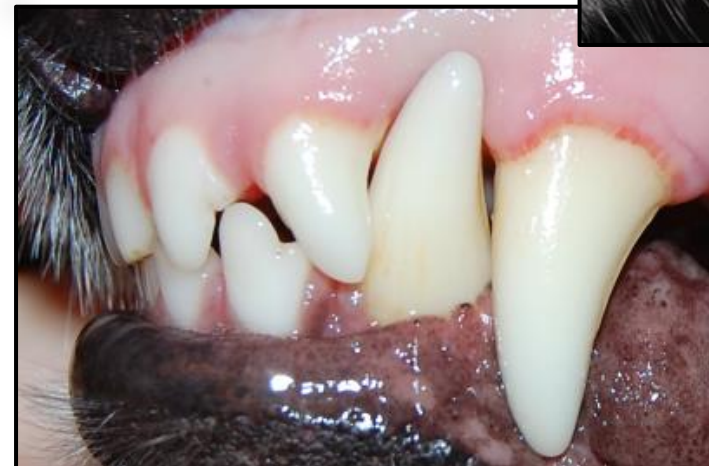
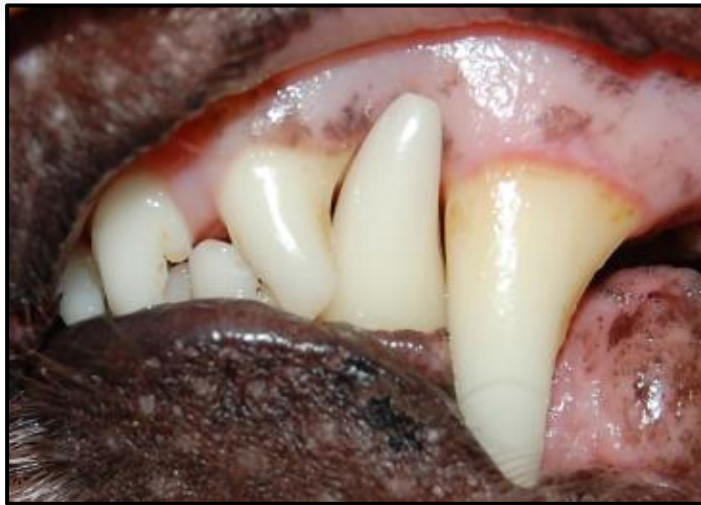Image 21

Image 22



Bilaga till RAS- Rasspecifika Avels Strategier för borzoi
Enligt beslut årsmöte 2010, fastställd årsmöte 2011, reviderad 2011-07-12
Sanktionerad av SKKs Domarkommitté, möte 2011-06-09, § 92
Översatt till engelska 2015-05-15

ILLUSTRATIONS OF **INCORRECT** BITES

Following pictures illustrates incorrect/ disqualifying bites for borzoi

Image 23

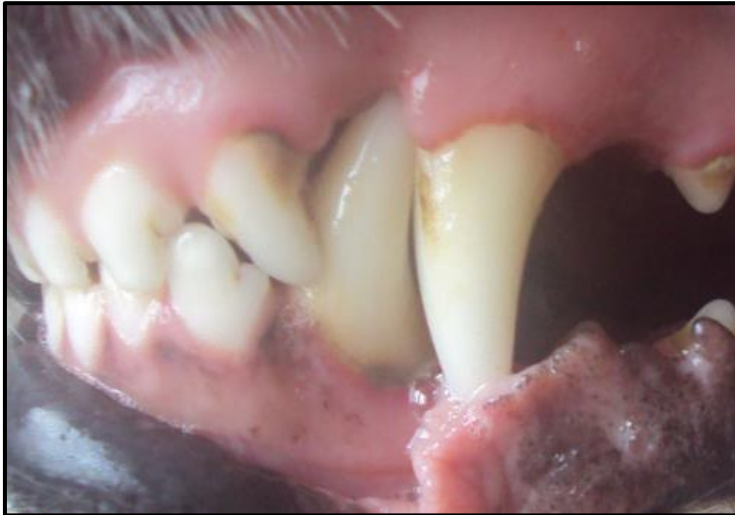

Image 23

Judging this dogs bite it is useful to consider to guideline; "you should be able to see the tip of the lower canine when the mouth is closed". In this dog you are not able to see the tip of the lower canine.

Image 24

This dog is 13 years old with a disqualifying bite. Even as a young dog it had a incorrect bite.

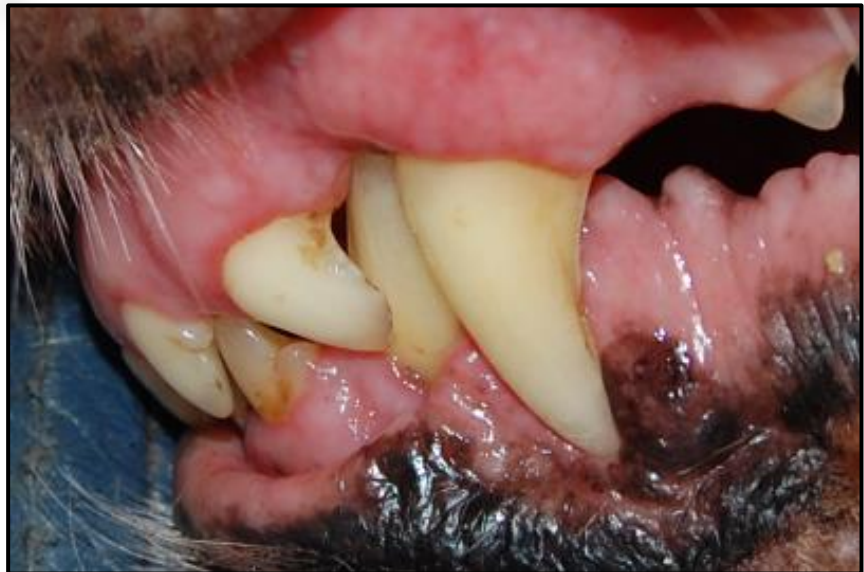

Image 24

To note, these two dogs- even so having disqualifying bites, never had any discomforts due to their canines. The one pictured in image 24 even so reached a respectable age for the breed!